

BOX 31-1 DIFFERENTIAL DIAGNOSIS: HEMOPTYSIS**Airway Disease**

Bronchitis (acute or chronic)
Bronchiectasis
Neoplasm (primary and metastatic)
Trauma
Foreign body

Parenchymal Disease

Tuberculosis
Pneumonia/lung abscess
Fungal infection
Neoplasm

Vascular Disease

Pulmonary embolism
Arteriovenous malformation
Aortic aneurysm
Pulmonary hypertension
Vasculitis (Wegener's granulomatosis, SLE, Goodpasture's syndrome)

Hematologic Disease

Coagulopathy (cirrhosis or warfarin therapy)
Disseminated intravascular coagulation
Platelet dysfunction
Thrombocytopenia

Cardiac Disease

Congenital heart disease (especially in children)
Valvular heart disease
Endocarditis

Miscellaneous

Cocaine
Post-procedural injury
Tracheal-arterial fistula

SLE, systemic lupus erythematosus.

Interventional Angiography

Bronchial arterial embolization is an effective first-line therapy and is the procedure of choice for patients unable to tolerate surgery, or those in whom bronchoscopy was unsuccessful. Hemostatic rates range from 91 to 98%, but as many as 20 to 50% of patients have early episodes of repeat bleeding. The risk of delayed bleeding may exist for up to 36 months.²¹⁻²⁴ In order to guide therapy, initial localization of bleeding by bronchoscopy or CT is preferred. Rare complications include arterial perforation and dissection.

Surgery

Emergency thoracotomy is reserved for life-threatening hemoptysis or for persistent, rapid bleeding that is uncontrolled by bronchoscopy and percutaneous embolization. Pulmonary arterial hemorrhage from tumor necrosis represents a surgical emergency.²⁵

DISPOSITION

Healthy patients with blood-streaked sputum and normal vital signs do not require imaging beyond plain chest radiography

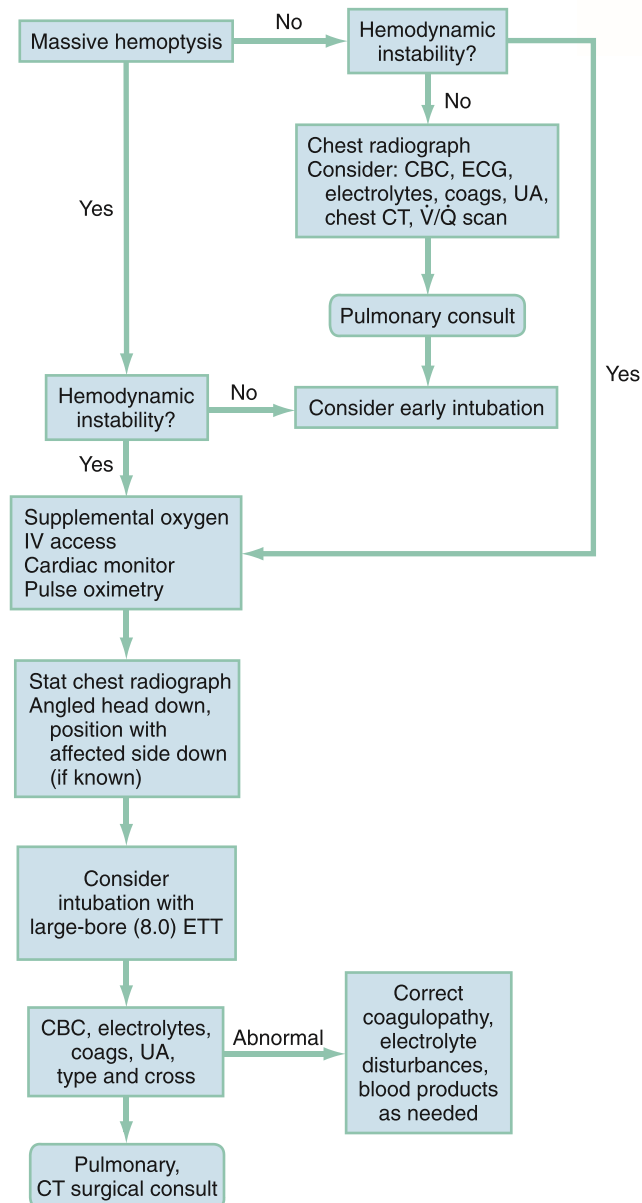


Figure 31-1. Emergency department management of hemoptysis. CBC, complete blood count; coags, coagulation studies; CT, computed tomography; ECG, electrocardiogram; ETT, endotracheal tube; IV, intravenous; UA, urinalysis; V/Q, ventilation-perfusion.

and can be discharged with follow-up. High risk patients with minor hemoptysis and all patients with moderate or large amounts of hemoptysis should undergo plain chest radiography followed by emergent chest CT. Brief hospitalization or admission to an observation unit for bronchoscopy should be considered. All patients with massive hemoptysis require admission to an intensive care unit and expedited multidisciplinary treatment involving the emergency physician, pulmonologist, and thoracic surgeon.

The references for this chapter can be found online by accessing the accompanying Expert Consult website.

Joshua L. Wright and John M. Wightman

■ PERSPECTIVE

Epidemiology and Pathophysiology

Most eye complaints are not immediately sight-threatening and can be managed by an emergency physician. Nontraumatic diseases, such as glaucoma and peripheral vascular disease leading to retinal ischemia, are more common with advancing age. Ocular injuries are the leading cause of visual impairment and blindness in the United States.¹ More patients with postoperative complications can be expected to present to the emergency department as more vision correction surgeries are performed.

The external and internal anatomy of the eye is depicted in Figure 32-1A and B. The globe has a complex layer of blood vessels in the conjunctiva, sclera, and retina. Redness reflects vascular dilation and may occur with processes that produce inflammation of the eye or surrounding tissues. Eye pain may originate from the cornea, conjunctiva, iris, or vasculature. Each is sensitive to processes causing irritation or inflammation.

■ DIAGNOSTIC APPROACH

Rapid and accurate triage is the most critical consideration in the approach to the red and painful eye. The first question should be, “Did anything get in your eye?” If so, the second question should be, “What do you think it is?” This helps separate trauma from nontrauma, but, more importantly, seeks to identify quickly eyes that may have been exposed to a caustic substance. Patients exposed to caustic substances require rapid decontamination to prevent permanent loss of visual acuity.

Differential Considerations

Diagnoses are classically divided into traumatic and nontraumatic. Traumatic pain and redness can be caused by caustic fluids and solid materials, low-velocity contact with a host of materials that can fall or be rubbed into the eye, higher velocity blunt-force impacts to the orbit or globe, or potentially penetrating injuries. Causes of nontraumatic pain and redness require a more detailed history, including contact lens use and questions directed toward determining the likelihood of systemic illnesses.

Pivotal Findings

Measurement of the patient’s best corrected visual acuity (i.e., with glasses on, if available) with each eye individually and with both eyes provides vital information when evaluating eye complaints. Only a few situations preclude early and accurate visual acuity testing. Eyes exposed to caustic materials should be decontaminated as soon as possible. Patients with sudden and complete visual loss in one eye require prompt funduscopic examination to determine the possibility of acute central retinal artery occlusion. This condition is readily apparent as a diffusely pale retina with indistinct or unseen retinal arteries (Fig. 32-2).

Other pivotal findings, which are more likely to be associated with a serious diagnosis, in patients with a red or painful eye are listed in Box 32-1.

History

Chief complaints of pain can be manifestations of a variety of sensations. When carefully questioned, some patients may differentiate between itching, burning, dull pain, sharp pain, and perception of a foreign body. Itching tends to be more often due to blepharitis, conjunctivitis, or dry eye syndrome. Burning is associated with these conditions and with other mostly extraocular problems such as irritation of a pterygium or pinguecula, episcleritis, or limbic keratoconjunctivitis. Dull pain may be a manifestation of increased intraocular pressure (IOP) or referred from an extraorbital process such as sinusitis, migraine headache, or temporal arteritis. Sharp pain generally results from abnormalities of the anterior eye, such as keratitis, uveitis, and acute angle-closure glaucoma. A foreign body sensation is more typical of corneal irritation or inflammation.

A chief complaint of redness commonly results from palpebral or limbal injection of the conjunctiva. However, free blood can be noted behind the bulbar conjunctiva (i.e., subconjunctival hemorrhage) or in the anterior chamber (i.e., hyphema). Both of these can be spontaneous or post-traumatic. Spontaneous subconjunctival hemorrhages may follow coughing or straining or may be due to systemic hypertension. Often, it occurs without any identifiable precipitating incident and is simply noticed by the patient when looking in the mirror. Spontaneous subconjunctival hemorrhage is painless, and the presence of pain raises concern for a more serious cause of the hemorrhage, such as direct globe injury. Hyphema of

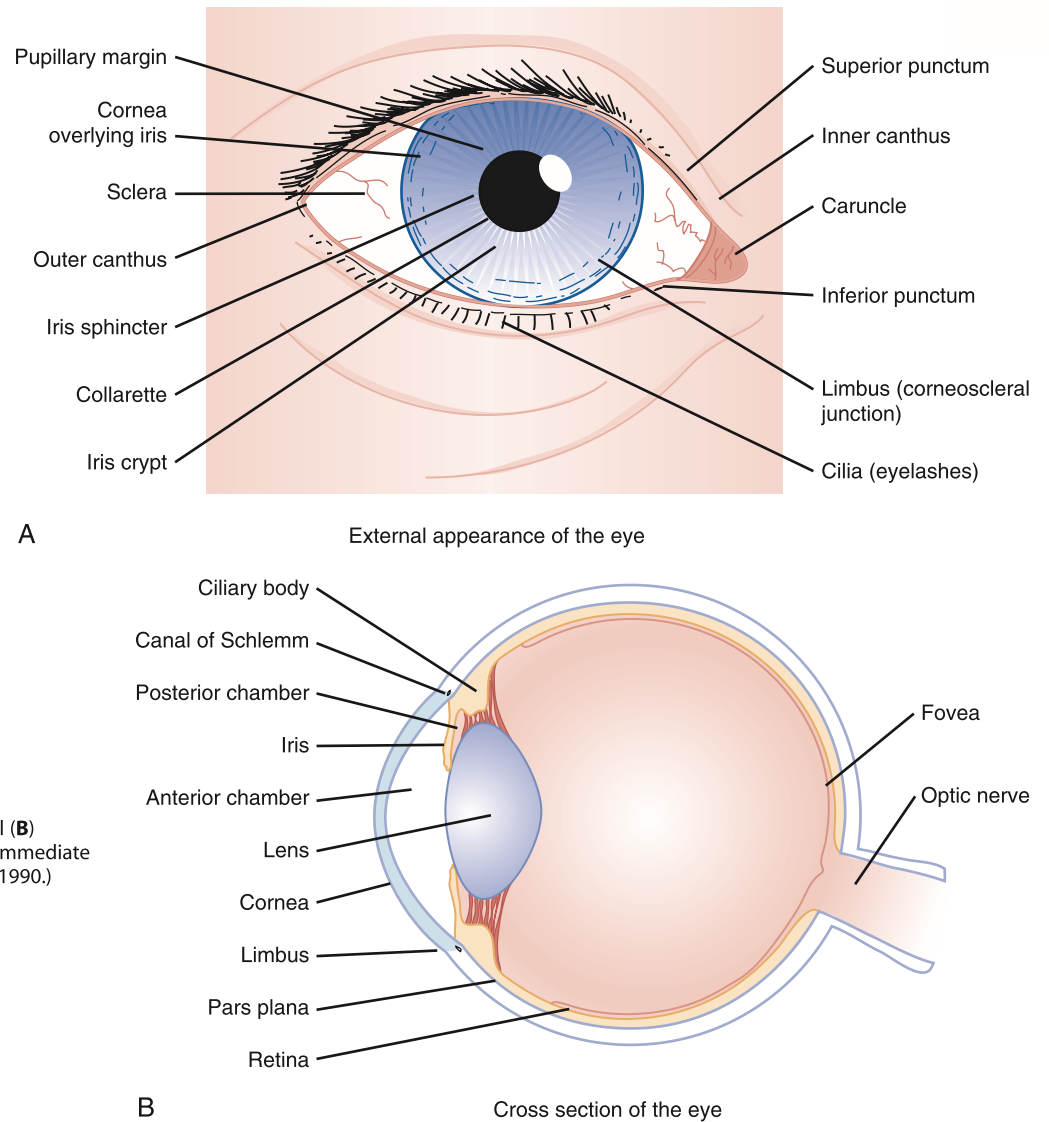


Figure 32-1. External (A) and internal (B) anatomy. (From Ragge NK, Easty DL: Immediate Eye Care. St. Louis, Mosby-Year Book, 1990.)

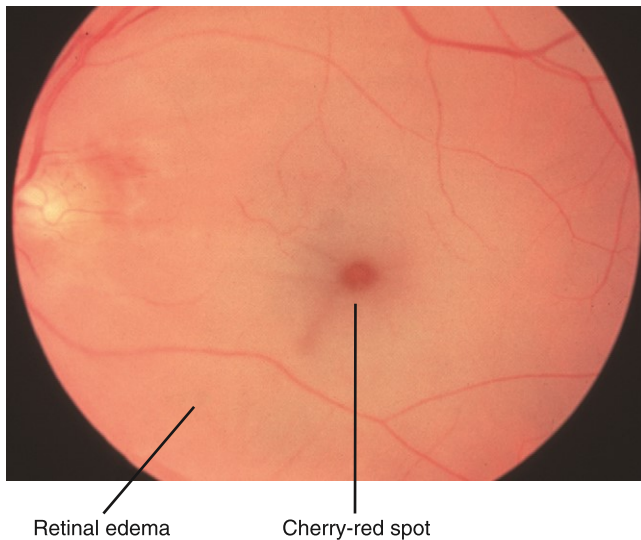


Figure 32-2. Key funduscopic findings in acute central retinal artery occlusion include general pallor of the retina (except for a characteristic cherry-red spot where the perfused choroid shows through the thinner fovea) and attenuation of retinal arteries (possibly with retinal veins preserved as in the photograph). (From Kaiser PK, Friedman NJ, Pineda R, II: The Massachusetts Eye and Ear Infirmary Illustrated Manual of Ophthalmology, 2nd ed. Philadelphia, WB Saunders, 2004, p 297.)

BOX 32-1

PIVOTAL FINDINGS MORE LIKELY ASSOCIATED WITH A SERIOUS DIAGNOSIS IN PATIENTS WITH A RED OR PAINFUL EYE

- Severe ocular pain
- Persistently blurred vision
- Proptosis
- Reduced ocular light reflection
- Corneal epithelial defect or opacity
- Limbal injection (i.e., ciliary flush)
- Pupil unreactive to a direct light stimulus
- Wearer of soft contact lenses
- Neonate
- Immunocompromised host
- Worsening signs after 3 days of pharmacologic treatment

Adapted and reprinted, with permission, from Trobe JD: The Physician's Guide to Eye Care. San Francisco, Foundation of the American Academy of Ophthalmology, 2001.

sufficient size to be noted by the patient or bystander usually arises with pain and blurred vision.

Other subjective findings may be transient and detected only by history. The patient may relate lid swelling, tearing, discharge, crusting, or sensitivity to light. Lid swelling can be caused by inflammatory and noninflammatory processes. Concurrent erythema of the lid favors the former. In the absence of trauma or other external irritant (e.g., contact dermatitis), inflammatory processes include primary lid problems such as hordeolum (i.e., stye) or blepharitis as well as extension from concomitant conjunctivitis or cellulitis in orbital or periorbital structures. When pain is present, tearing is usually secondary. Discharge and crusting are most commonly associated with conjunctivitis, whether allergic, viral, or bacterial. Blepharitis, dacryocystitis, and canaliculitis are other inflammatory processes that may create a discharge and subsequent crusting.

Other eye status review questions include the following:

- Are contact lenses used? If so, what type, how are they cleaned, and how old are the lenses? Has there been a change in the pattern of use (especially increased use)? Were the lenses worn for a particularly long period recently? Are there problems with the lenses drying out? Does insertion of the lenses worsen or relieve the symptoms?
- Are glasses worn? If so, when was the last assessment for adequate refraction?
- Has previous eye surgery or injury occurred?
- What is the patient's usual state of health?
- What medications are being taken? Are there any allergies, including environmental allergies?

Physical Examination

A complete eye examination usually includes eight components, although many patients require only a limited or directed eye examination, depending on the presentation.² The mnemonic VVEEPP (pronounced "veep") plus slit-lamp and funduscopic examinations represent these components (Box 32-2).³ Slit-lamp examination is recommended for any complaint involving trauma and for any medical presentation involving foreign body sensation or alteration of vision.

BOX 32-2 COMPLETE EYE EXAMINATION

Visual acuity (best possible using correction)
 Visual fields (tested by confrontation)
 External examination
 Globe position in orbit
 Conjugate gaze
 Periorbital soft tissues, bones, and sensation
 Extraocular muscle movement
 Pupillary evaluation (absolute and relative)
 Pressure determination (tonometry)
 Slit-lamp examination
 Lids and lashes
 Conjunctiva and sclera
 Cornea (with fluorescein in some cases)
 Anterior chamber
 Iris
 Lens
 Funduscopic examination

Adapted from Wightman JM, Hurley LD: Emergency department management of eye injuries. *Crit Decis Emerg Med* 12:1, 1998.

Funduscopic examination is usually pursued if there is visual loss, visual alteration, or suggestion of serious pathology in the history and initial physical examination. A thorough physical examination can be conducted in the following order.

Visual Acuity

The initial determination of a patient's visual acuity provides a baseline from which deterioration or improvement may be followed. It is also predictive of functional outcome after ocular trauma. Visual acuity is quantitatively assessed by use of a Snellen chart test at a distance of 20 feet (6 m) or a Rosenbaum chart at a distance of 14 inches. Young patients who cannot yet read letters and numbers should be tested with an Allen chart that depicts easily recognizable shapes. Each eye is tested separately with the opposite eye carefully covered. Patients who present without their prescribed corrective lenses may be evaluated by having them view the chart through a pinhole eye cover, which negates most refractive errors in vision.

If the patient cannot distinguish letters or shapes on a chart, visual acuity must be determined qualitatively. Any printed material suffices. The result may be recorded as, for example, "patient able to read newsprint at 3 feet." If this is not possible, visual acuity is recorded as:

- Unable/able to count fingers (CF)
- Unable/able to perceive hand motion (HM)
- Unable/able to perceive light (LP)

Visual Field Testing

Confrontation is the most common method of testing visual fields in the emergency department.⁴ Detection of a scotoma usually represents a retinal problem. However, glaucoma may cause scotomata that can be crescent-shaped, involve just the binasal visual fields, or affect all peripheral vision. Hemi- or quadrantanopia is more commonly a problem of the neural pathways to the brain.

External Examination

Gross abnormalities are assessed by a visual inspection of both eyes simultaneously. Findings may be more apparent if compared with the opposite side. Fractures of facial bones are associated with ocular injuries, some of which require immediate intervention by an ophthalmologist.⁵

Globe position is part of the external examination. Subtle exophthalmos and enophthalmos are rare, and are best detected by looking inferiorly, tangentially across the forehead, from over the patient's scalp.⁶ Exophthalmos may have traumatic or nontraumatic causes, but is due to increased pressure or a space-occupying lesion within the orbit, which may manifest as pain. Medical causes include cellulitis or intraorbital or lacrimal tumors. Hyperthyroidism may cause enlargement of extraocular muscles. The most important cause of exophthalmos in the emergency department is retrobulbar hematoma, a condition characterized by hemorrhage within the bony orbit, behind the globe. Orbital compartment syndrome pushes the globe forward, stretching the optic nerve and retinal artery and increasing IOP. The resulting microvascular ischemia is sight-threatening if sufficiently severe and persistent. Orbital emphysema and inflammation caused by a retained foreign body behind the eye are other causes of exophthalmos. The discovery of exophthalmos should prompt ocular tonometry measurements to determine the urgency of intervention. Trauma, particularly penetrating globe injury with extrusion

of vitreous, can cause the globe to recede into the orbit, but the most common cause of enophthalmos is actually pseudoenophthalmos when the contralateral globe is proptotic.

Inspection also involves examination of the upper and lower palpebral sulci for foreign bodies or other abnormalities. The lower sulcus is easily viewed after manual retraction of the lower lid toward the cheek and having the patient gaze upward. The upper sulcus is inspected by pulling its lashes directly forward and looking under the lid with white light. The lid can then be everted by pressing a cotton-tipped applicator in the external lid crease and folding the lid margin over the applicator.

Extraocular Muscle Function

Limitation of ocular movement in one eye may be detected by having the patient follow the examiner's finger or a bright light through the cardinal movements of gaze. The eyes may move in a disconjugate fashion, or the patient may admit to diplopia if asked. Diplopia on extreme gaze in one direction may indicate entrapment of one of the extraocular muscles within a fracture site, but more often is caused simply by edema or hemorrhage related to the injury and is functional rather than actual entrapment. In the absence of trauma, diplopia is rarely associated with redness or pain.

Pupillary Evaluation

The pupils are inspected for abnormalities of shape, size, and reactivity. These examinations are conducted with light specifically directed into the pupil and by means of the swinging flashlight test.

Previous surgery (e.g., iridotomy for cataract extraction) and synechiae from prior iritis or other inflammatory condition are the most common causes of irregularly shaped pupils. Asymmetrically sized pupils may represent normal or pathologic conditions. Physiologic anisocoria is a slight difference in pupil size that occurs in up to 10% of the population. Topical or systemic medications, drugs, and toxins may cause abnormal pupillary constriction or dilation.

Pathologic reasons for failure of one pupil to constrict with a direct light stimulus include globe injury, abnormalities of afferent or efferent nerves, and paralysis of the ciliaris or sphincter pupillae muscles in the iris. Potentially serious problems, which also cause pain and redness, include uveitis and acute angle-closure glaucoma.

The swinging flashlight test is used to determine whether a relative afferent pupillary defect (RAPD) exists.⁴ The patient fixes the gaze on a distant object and the examination room is darkened. The size of the pupils in lowered light is noted, and unless there is physiologic anisocoria, the pupils should be equal in size. The direct and consensual light responses of the eyes are compared as a light source, angled into the pupil from in front of the cheeks, is swung back and forth between the two. When the light source shines into an eye with an RAPD, the pupil dilates because the consensual response from withdrawal of light from the opposite eye with normal afferent activity is stronger than the direct constrictive response to light in the affected eye with inhibited afferent activity. It is termed "relative" because the response is compared with that of the opposite side as the light source is alternated between eyes. An RAPD may be partial or complete and due to inhibition of light transmission to the retina because of vitreous hemorrhage, loss of some or all of the retinal surface for light contact because of ischemia or detachment, or the presence of lesions affecting the prechiasmatic optic nerve (e.g., optic neuritis).

Pressure Determination

Ocular tonometry is usually the last examination performed in the emergency department. Common methods of determining the IOP in the emergency department include use of electronic, manual (e.g., Schiøtz), or applanation tonometers. IOPs in the 10- to 20-mm Hg range are considered normal. Causes of intraocular hypertension include glaucoma in its many forms, suprachoroidal hemorrhage, and space-occupying retrobulbar pathology. Patients presenting with IOPs exceeding 20 mm Hg should have ophthalmologic consultation. Rapid treatment is usually not necessary until the pressure exceeds 30 mm Hg.

Slit-Lamp Examination

The slit lamp permits a magnified, binocular view of the conjunctivae and anterior globe for diagnostic purposes and to facilitate delicate procedures. It allows depth perception in otherwise clear structures, such as the cornea, aqueous humor, and lens. The slit-lamp examination can include the following:

- Lids and lashes may be inspected for blepharitis and pointing of a lid abscess (i.e., hordeolum). The inner canthus and lacrimal punctum may be better viewed for evidence of dacryocystitis.
- Punctures, lacerations, and inflammatory patterns of the conjunctiva or sclera may be discovered with magnification.
- Corneal abrasions, ulcers, foreign bodies, and other abnormalities may be seen. The depth of these lesions may be accurately assessed with an angled beam. Edema, which appears as a white haze or cloudiness within clear structures, can be differentiated within the epithelium or deeper stroma.
- The anterior chamber may be examined for cells (e.g., red and white blood cells) and "flare." Cells are seen as small floating objects caught in the beam of a highly angulated slit-lamp light, as dust floating in the movie theater glows from the reflected light of the projector beam. Flare is a diffuse haziness, related to cells and proteins suspended in the aqueous humor, and is often visible only when illuminated directly (Fig. 32-3). It usually represents deep

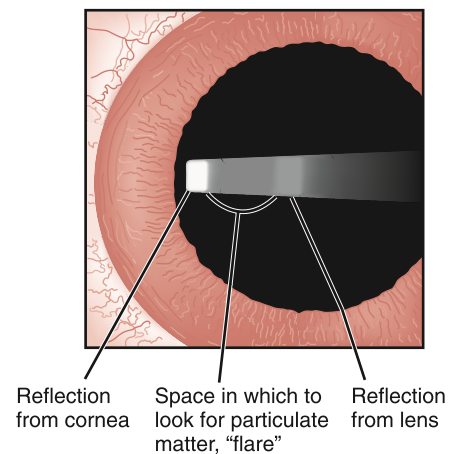


Figure 32-3. Technique of slit-lamp examination with a short, narrow light beam projected from an extreme temporal angle across the contrasting black pupil to better find cells or "flare" indicative of acute anterior uveitis. (From Rague NK, Easty DL: Immediate Eye Care. St. Louis, Mosby-Year Book, 1990.)

inflammation of the eye and is often seen in iritis. Collections of layered blood or pus in the dependent portions of the anterior chamber are called hyphema or hypopyon, respectively, and are graded by the percentage of the vertical diameter of the visible iris when the head is upright. Foreign bodies that have penetrated the cornea may be found floating in the anterior chamber.

- The trabeculated pattern of the iris can be seen in detail. Spiraling muscle fibers may be seen in acute angle-closure glaucoma. If the beam is shown almost coaxially with the examiner's line of sight such that the red reflex is elicited, tears in the iris may be seen by light returning through the iris itself instead of just through the pupil.
- The lens should be examined for position, general clarity, and the presence of opacities or foreign bodies. The type and position of any lens implants can also be better assessed during a slit-lamp examination.

Direct Funduscopy Examination

Emergency physicians most commonly perform a nondilated funduscopy examination because there are several eye conditions in which dilation may be harmful (e.g., glaucoma). Iridodialysis, lens dislocation, and conditions requiring early intervention are usually identifiable along the visual axis.

Inability to obtain a red reflex or visualize the fundus of the eye can be due to:

- Opacification of the cornea, most commonly by edema secondary to injury or infection
- Hyphema or hypopyon within the anterior chamber
- Extremely miotic pupil
- Cataract of the lens
- Blood in the vitreous or posterior eye wall
- Retinal detachment

In the absence of trauma, few posterior findings are associated with chief complaints of external redness. Findings associated with visual loss include pallor of the retina indicating ischemia, "cupping" of the optic disk indicating glaucoma, indistinctness of disk margins indicating papilledema or optic neuritis or neuropathy, air or plaque emboli in retinal arteries, and a host of other signs indicating more chronic ocular or systemic pathology not normally amenable to management in the emergency department.

Bedside Testing

Fluorescein solution and the cobalt blue lamp are the best means for identifying damage to the corneal epithelium, including that which cannot be seen with conventional slit-lamp examination. Fluorescein highlights defects, making them easy to identify, because the fluorescing liquid is thicker in defects than it is across the normally smooth corneal surface. Use of fluorescein may reveal corneal abrasions and ulcers as well as damage from keratitis related to chemicals, ultraviolet light, or infections (e.g., herpes).

Relief of discomfort after instillation of a topical anesthetic can be used as a diagnostic test for an external source of pain. In general, abolition of pain by local anesthetic drops indicates pain of corneal origin. Modest but incomplete relief suggests a conjunctival process. Intraocular pain is not diminished by local anesthetic solution.⁷ When ocular penetration is suggested, Seidel's test can be used. This test involves placing a fluorescein strip directly over an area of possible corneal disruption. The high localized concentration of fluorescein may facilitate identification of the corneal defect with a slit lamp by allowing visualization of leaking aqueous fluid diluting the fluorescein. This test does not work on the conjunctiva overly-

ing the sclera, and a negative test result does not rule out a full-thickness corneal injury.

Ancillary Testing

An erythrocyte sedimentation rate may be used to evaluate for temporal arteritis, which may arise with eye pain and decreased visual acuity.

Infections are usually evident by examination, and laboratory tests such as a complete blood count are not necessary. Microbiologic cultures are rarely ordered in the emergency department.

Plain radiography is used to identify facial fractures associated with facial or ocular trauma or indirectly by detecting an air-fluid level in the orbit or fluid in the paranasal sinuses. Computed tomography (CT), using 1.5-mm axial and coronal cuts, provides superior imaging, but is not necessary in many cases.

CT also reliably localizes metal and many nonradiopaque foreign bodies in the globe and orbit. It can also detect small amounts of intraocular air following penetrating trauma. Magnetic resonance imaging (MRI) clearly delineates the orbital and retro-orbital structures, but cannot be employed with metallic (magnetic) foreign bodies, which can migrate to cause additional damage.⁸ It is less often used in emergency eye assessment, for which, in general, CT is the initial imaging modality of choice.⁹ Ultrasonography is more sensitive for detecting intraocular foreign bodies, but CT is better at delineating the damage caused by them, so they are complementary tests.¹⁰

■ DIFFERENTIAL DIAGNOSIS

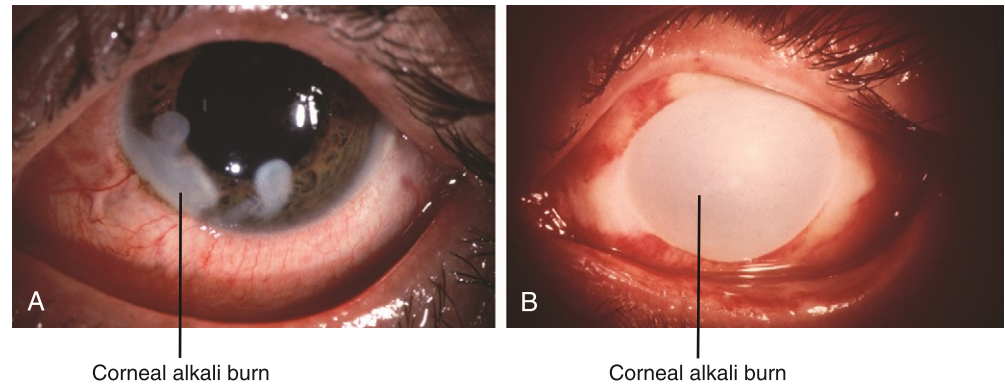
Clinical findings most indicative of serious eye disorder are listed in [Box 32-1](#).

Critical Diagnoses

Caustic injury to the eye can rapidly lead to a destructive keratoconjunctivitis ([Fig. 32-4A and B](#)) if the agent is not removed immediately. The diagnosis is made on history alone, before any other examination is performed. Early and copious irrigation is indicated. Many patients have already undergone extensive irrigation at the job site, but when the exposure has occurred in the home, irrigation prior to arrival in the emergency department is uncommon. Alkaline caustic agents cause a liquefactive necrosis of the cornea by progressively reacting with the corneal layers, and destruction is severe and relentless. Continuous irrigation is the only effective method to terminate the reaction and should be continued for at least 30 minutes. Acid injury is much less severe and requires less irrigation than alkaline exposures, but irrigation should continue until the pH of the tears is neutral or the patient is essentially asymptomatic.

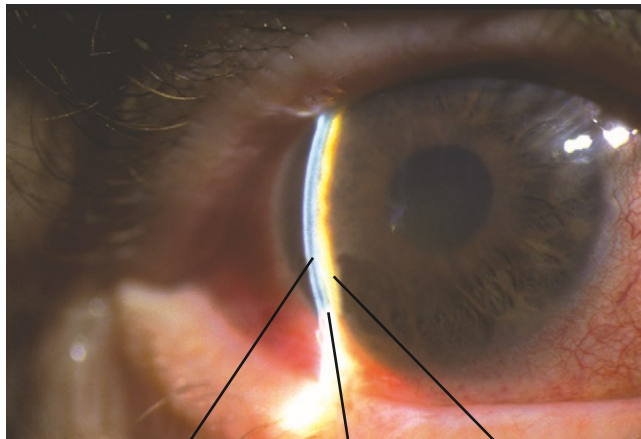
Acute angle-closure glaucoma is a relatively rare but important critical diagnosis to make in the emergency department. Patients present with pain, the onset of which is often sudden in low-light conditions requiring pupillary dilation through contraction and thickening of the iris peripherally. The iris becomes immobile and often irregular, and the pupil is commonly fixed at 5 to 6 mm in diameter. Inability of the pupil to constrict may result in photophobia, and accommodation may be affected. These reactions and the increased IOP can lead to frontal headache, nausea, and vomiting. As inflammation progresses, limbal injection of the conjunctiva is almost universally seen. [Figure 32-5](#) demonstrates many of these findings. Immediate medical intervention in the emergency

Figure 32-4. **A**, Alkali burn demonstrating corneal burns and conjunctival injection on the day of the accident. **B**, Complete corneal tissue destruction 7 days after alkali burn. (From Kaiser PK, Friedman NJ, Pineda R, II: *The Massachusetts Eye and Ear Infirmary Illustrated Manual of Ophthalmology*, 2nd ed. Philadelphia, WB Saunders, 2004.)



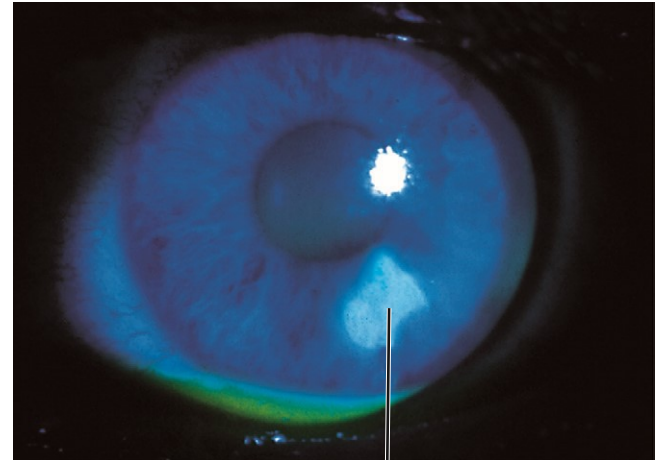
Corneal alkali burn

Corneal alkali burn



Posterior cornea Slit-beam Iris surface

Figure 32-5. Primary angle-closure glaucoma with very shallow anterior chamber and iridocorneal touch (no space between slit-beam view of cornea and iris). (From Kaiser PK, Friedman NJ, Pineda R, II: *The Massachusetts Eye and Ear Infirmary Illustrated Manual of Ophthalmology*, 2nd ed. Philadelphia, WB Saunders, 2004.)



Corneal abrasion

Figure 32-6. Corneal abrasion demonstrating fluorescein pooling of a small inferior epithelial defect. (From Kaiser PK, Friedman NJ, Pineda R, II: *The Massachusetts Eye and Ear Infirmary Illustrated Manual of Ophthalmology*, 2nd ed. Philadelphia, WB Saunders, 2004.)

department and urgent ophthalmologic consultation are warranted.

Retrobulbar hematoma (blood) is usually caused by orbital trauma, but it can also occur spontaneously in patients with coagulopathy. Retrobulbar abscess (pus) or emphysema (air) can also occur.^{11,12} Elevated IOP in any of these conditions constitutes orbital compartment syndrome and a surgical emergency. Emergency intervention is to decompress the orbit by performing lateral canthotomy and cantholysis.^{13,14}

Emergent Diagnoses

Most emergent diagnoses involve some kind of inflammation secondary to trauma, infection, or systemic disease. These include keratitis, anterior uveitis, scleritis, and endophthalmitis. Any of these may be complications of surgical procedures, and an appropriate ophthalmologic history must be obtained.

Keratitis, or inflammation of the cornea, is most commonly viral in origin but can also be caused by exposure to intense ultraviolet light (e.g., snow blindness, arc welder's blindness), various chemicals, or ischemia related to contact lens use. Patients present with an intense foreign-body sensation, ciliary spasm causes photophobia that is often severe, and the affected eyes are often clenched shut. Topical anesthesia provides immediate (but temporary) relief of pain, thus reinforcing the

corneal origin of the process and facilitating examination and definitive diagnosis.⁶ Corneal abrasions are very common and may be identified by white light or fluorescein-facilitated blue light using a slit lamp or any other magnification (Fig. 32-6). Following thorough irrigation, thermal and chemical burns must receive a careful slit-lamp examination for potential full-thickness injury. If this is not found, the corneal injury may be treated similarly to an abrasion.

In immunocompetent hosts, corneal ulcerations are most commonly due to overuse of contact lenses. They are seen as a denuding of epithelium with surrounding edema, the increased interstitial water of which is seen as whitish clouding of the normally clear tissue (Fig. 32-7). Almost all ulcerations require same-day evaluation by an ophthalmologist. Infections of the cornea with herpes simplex virus can rapidly lead to opacification and significant visual loss. It is most commonly recognized by a characteristic dendritic pattern of fluorescein pooling under blue light (Fig. 32-8). Anterior uveitis, which includes iritis and iridocyclitis, often occurs secondary to a traumatic injury or infectious process or can be associated with serious systemic immune diseases, such as adult and juvenile rheumatoid arthritis, sarcoidosis, and ankylosing spondylitis.

Scleritis is rare and may be difficult to differentiate from episcleritis, which is somewhat more common and a more

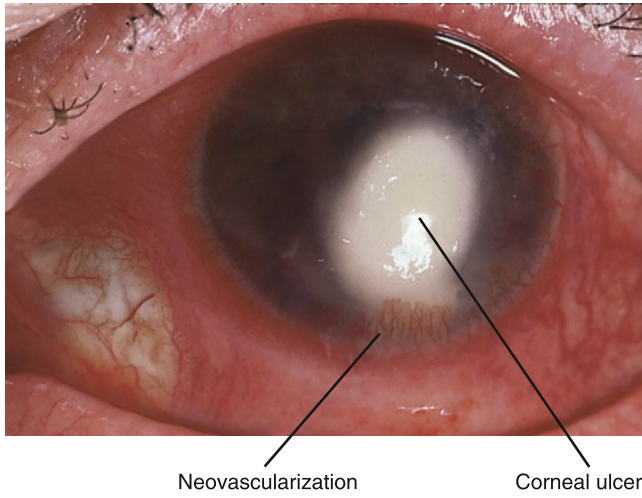


Figure 32-7. Bacterial keratitis demonstrating large, central *Streptococcus pneumoniae* corneal ulcer. Note the dense, white corneal infiltrate and the extreme conjunctival injection. (From Kaiser PK, Friedman NJ, Pineda R, II: The Massachusetts Eye and Ear Infirmary Illustrated Manual of Ophthalmology, 2nd ed. Philadelphia, WB Saunders, 2004.)

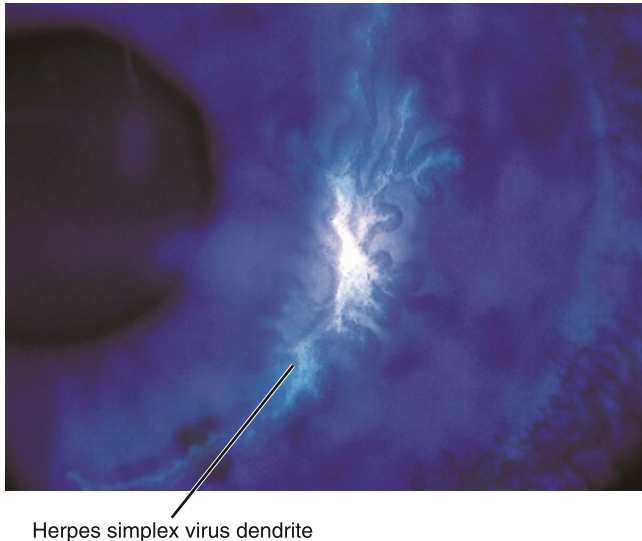


Figure 32-8. Patient demonstrating fluorescein pooling of herpes simplex virus dendrite. (From Kaiser PK, Friedman NJ, Pineda R, II: The Massachusetts Eye and Ear Infirmary Illustrated Manual of Ophthalmology, 2nd ed. Philadelphia, WB Saunders, 2004.)

benign inflammation. The former is commonly idiopathic but may be associated with a systemic inflammatory process, such as a connective tissue disease, gout, or infection (e.g., Lyme disease, syphilis, tuberculosis). Eye redness in episcleritis results from dilation of the episcleral blood vessels just underneath the conjunctiva, usually in a small sector of the visible portion of the globe. If the location of the involved layer is in doubt, a topical anesthetic allows the examiner to move the conjunctiva and its contained vessels with a cotton-tipped applicator, thus differentiating between vessels of scleral or conjunctival origin. The pain of scleritis is typically slower in onset but is often described as a severe “boring” pain that radiates to the ipsilateral forehead, cheek, or jaw. Engorgement of scleral vessels is usually more prominent and more diffuse than that of the episcleral vessels in episcleritis. A bluish hue may be seen as the underlying pigmented epithelium shows through the edematous, and hence more

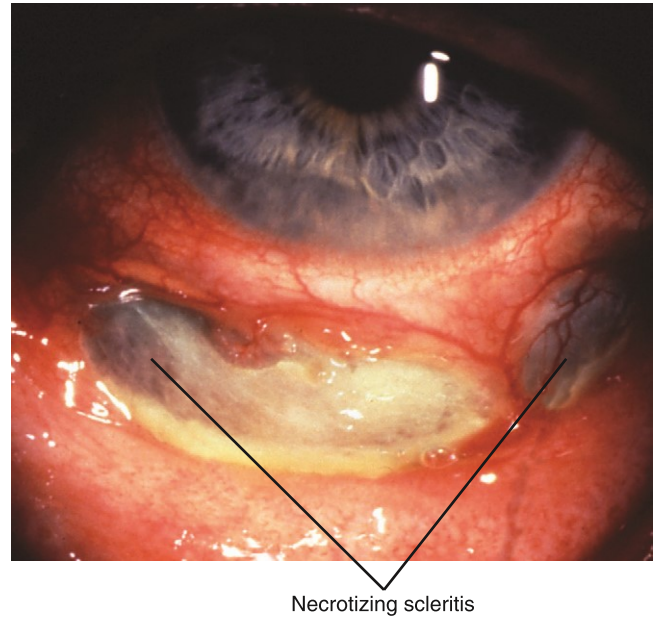


Figure 32-9. Diffuse scleritis with slight bluish region in addition to injection of scleral, episcleral, and conjunctival vessels. (From Kaiser PK, Friedman NJ, Pineda R, II: The Massachusetts Eye and Ear Infirmary Illustrated Manual of Ophthalmology, 2nd ed. Philadelphia, WB Saunders, 2004.)

translucent, sclera (Fig. 32-9). Scleritis may be associated with anterior uveitis, cataract, and secondary glaucoma.

Endophthalmitis usually results from an infection of structures inside the globe. It is most common following penetrating trauma but may begin after hematogenous seeding from a remote or systemic infection, particularly in immunocompromised hosts. Unless it is detected early, and is responsive to aggressive antimicrobial therapy, endophthalmitis is a devastating process that frequently requires enucleation.

Urgent Diagnoses

Penetrating ocular trauma is evaluated by history (e.g., working with high-speed grinding equipment), examination (extrusion of aqueous humor or other globe content; direct visualization of a foreign body in the anterior chamber, vitreous, or retina), or identification of the offending object by biplanar plain radiography, thin-cut CT, or ultrasonography. MRI should not be used if there is any possibility that the foreign object may be metallic. Indirect indicators of globe penetration are hyphema, an irregularly shaped pupil from traction on or injury to the iris' attachments, or lack of a red reflex. If penetrating ocular injury is confirmed or if the possibility persists after evaluation, an ophthalmologic consultation is indicated.⁴

Spontaneous or traumatic hyphema is often managed conservatively. Blood in the anterior chamber is usually the result of direct ocular trauma and may be associated with traumatic mydriasis or an obvious tear of the iris. If penetration and rupture can be reasonably excluded, the hyphema should be graded and IOP determined. Intraocular hypertension (or hypotension in the case of occult globe rupture) following trauma must also be evaluated by an ophthalmologist urgently. Inability to view posterior structures through the anterior blood may necessitate radiologic or ultrasonographic imaging.

Diagnostic Algorithm

A recommended algorithmic approach to the patient with an acute red eye is provided in Figure 32-10.

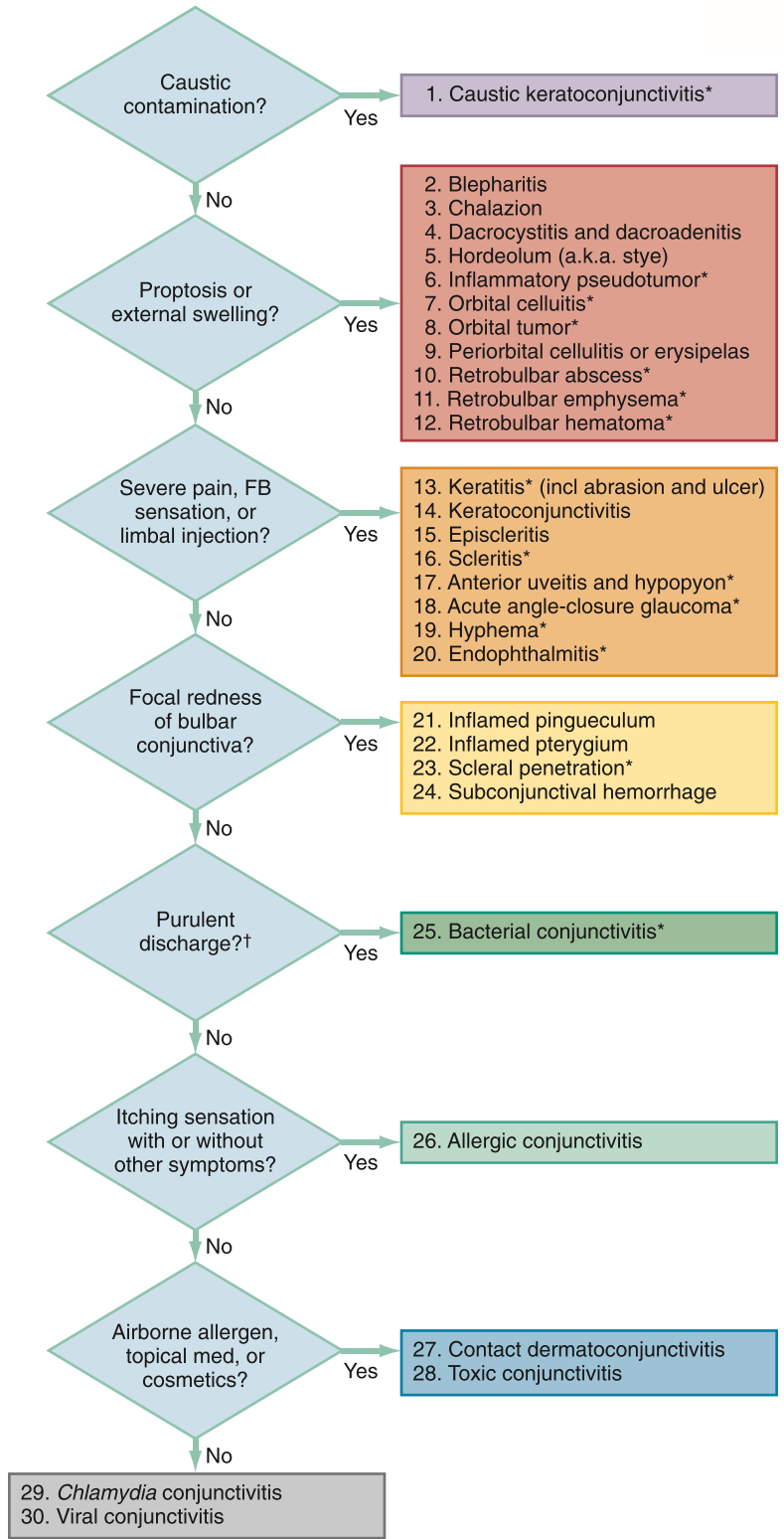


Figure 32-10. Diagnostic algorithm for red eyes. *Indicates potentially serious diagnoses if not identified on initial emergency department evaluation. †Purulent implies true pus, as opposed to the mucoid discharge more commonly associated with nonbacterial causes of conjunctivitis. a.k.a., also known as; FB, foreign body; incl, including. (Modified from Trobe JB: The Physician's Guide to Eye Care. San Francisco, Foundation of the American Academy of Ophthalmology, 2001.)

EMPIRICAL MANAGEMENT

Irrigation

Any clean water is appropriate for irrigation, and prompt initiation takes precedence over procurement of a particular irrigating solution. The most important principles are *rapid and copious* dilution and removal of the offending material. An eyewash station or faucet with tap water may be employed.

Normal saline may be instilled through the end of macrodrip intravenous administration tubing. If there is no gross eye injury, a Morgan lens may be attached to this tubing, but emergency department staff do not have to help the patient hold the eye open. Quickly administering two drops of topical anesthetic and allowing 30 seconds or so for the anesthetic to become effective greatly facilitates patients' tolerance of the prolonged irrigation required. It is recommended that the first 500 to 1000 mL of irrigation fluid be

administered while examining the eye; then the Morgan lens may be placed.

Pain Relief

Pain often interferes with obtaining an adequate assessment. A topical anesthetic, such as proparacaine 0.5%, may facilitate cooperation in patients with possible injury or inflammation of the anterior eye by reducing pain and blepharospasm long enough to obtain a targeted history and focused examination. Topical anesthetic agents should not be given to patients to use at home. Parenteral or oral analgesics can be used for severe deep pain not amenable to topical relief in the emergency department, or for outpatient management of discomfort after discharge.

Mydriatic and Cycloplegic Agents

Dilation of the pupil is not usually necessary in the emergency department for funduscopic examination, but may relieve pain associated with ciliary spasm in anterior uveitis. Mydriatic agents (e.g., phenylephrine, tropicamide) merely prevent constriction of the pupil by paralyzing the sphincter pupillae muscle of the iris. Cycloplegic agents (e.g., cyclopentolate, homatropine) paralyze the ciliaris muscle, with an accompanying mydriatic effect. The agent chosen should be guided by the desired length of time of mydriasis for the particular condition being treated (Table 32-1). Mydriatic agents are contraindicated in patients with narrow-angle glaucoma.

Antimicrobial Agents

Most conjunctivitis is viral in origin, but it is often difficult to distinguish bacterial from viral types of conjunctivitis based solely on clinical grounds.^{15,16} Although no definitive empirical evidence dictates the use of antibiotic solutions or ointments for surface infections, the use of broad-spectrum topical antibiotics in cases of proven bacterial conjunctivitis is associated with benefit showing significantly higher clinical remission rates.¹⁷ Antimicrobial prophylaxis should be used for penetrating wounds to prevent bacterial keratitis or endophthalmitis.

Antibiotics are typically used to treat identified or suggested bacterial infections, even if the exact bacterial agent has not been determined. The most common causes of bacterial conjunctivitis are nontypable *Haemophilus influenzae*, *Streptococcus pneumoniae*, and *Staphylococcus aureus*.^{18,19} Trachoma, a chronic keratoconjunctivitis caused by *Chlamydia trachomatis*, is the

most common infectious cause of blindness.²⁰ Bacterial keratitis is usually seen in contact lens wearers, particularly those who wear them overnight.²¹ In descending order of frequency of cultured organisms, microbial keratitis is caused by *Pseudomonas aeruginosa*, streptococcal or staphylococcal species, filamentous fungi, nonpseudomonal gram-negative rods, *Acanthamoeba*, other bacteria, and yeast.²²

The most common organisms cultured from deeper eye structures, particularly following open-globe injuries, are *Bacillus cereus*, *Propionibacterium acnes*, and various species of *Bacillus*, *Streptococcus*, and *Staphylococcus*.^{23,24} While awaiting emergent ophthalmologic consultation for possible vitrectomy, empirical parenteral antibiotic combinations include cefazolin plus gentamicin or vancomycin plus cefotaxime, ceftazidime, or ceftriaxone. Possible cases of mycotic endophthalmitis have historically been treated with amphotericin B,²³ though voriconazole has been shown to have good intraocular penetration, broad-spectrum activity, and relatively low systemic toxicity.²⁵

Open wounds also require tetanus prophylaxis, if the patient's immunization status is not up to date. There is no current evidence supporting the practice of administering tetanus immunization to patients with superficial corneal abrasions.

Other Protective Interventions

Significantly increased IOP must be reversed as rapidly as possible, often before the specific cause is known. After placing the patient in at least a 30° head-up position, two drops of timolol 0.5%, a topical beta-adrenergic blocking medication, should be administered as a first-line agent to decrease the production of aqueous humor. This may be followed by two drops of dorzolamide 2%, a topical carbonic anhydrase inhibitor, to reduce aqueous humor production further. If not available, 500 mg of acetazolamide may be given orally or intravenously. If the patient has sickle cell disease or trait, oral methazolamide 50 mg must be used instead. Patients with suggested intraocular hypertension who also have nausea or vomiting should receive a parenteral antiemetic so that they do not gag or vomit, which may further increase IOP.

Specific Management

Management of the specific entities listed in the diagnostic algorithm presented in Figure 32-10 is presented in Table 32-2. Specific management of ophthalmologic conditions is also discussed in Chapter 69.

■ SPECIAL CONSIDERATIONS

Pediatrics

A red eye in a neonate or infant is always abnormal. It is usually caused by corneal abrasion or infection. Corneal abrasions can also be a cause of inconsolable crying in an infant. Fluorescein examination helps to identify abrasions and herpes keratitis, acquired from the birth canal. *Chlamydia* infections may also be acquired during vaginal deliveries but may not arise for weeks. These infections should be treated with oral azithromycin as well as parenteral ceftriaxone to cover *Neisseria gonorrhoeae*. Conjunctivitis associated with respiratory symptoms or infiltrates on a chest radiograph in an infant younger than 3 months should be treated with an oral macrolide. Oral antibiotics are also indicated for conjunctivitis associated with otitis media. *Mycoplasma* is a common infectious agent in these cases, and a macrolide is indicated.¹⁴

Table 32-1

Duration of Action for Common Mydriatic and Cycloplegic Medications

NAME	CONCENTRATION (%)	COMMON DURATION	MAXIMUM DURATION
Ephedrine*	5.0	0.5–1 hr	3 hr
Phenylephrine*	2.5	0.5–1 hr	3 hr
Tropicamide	0.5	3–4 hr	6 hr
Cyclopentolate	0.5	12–18 hr	24 hr
Homatropine	1.0	1–2 days	3 days
Scopolamine	0.5	2–5 days	7 days
Atropine	0.5	5–10 days	14 days

*Mydriatic action only, no cycloplegic effect. Combination products such as Cyclymdril, which is cyclopentolate 0.2% and phenylephrine 10%, are also available.

Table 32-2

Management Algorithm for Red Eyes Extended from Diagnostic Algorithm in Figure 32-10

DIAGNOSIS FROM FIGURE 32-10	MANAGEMENT	CONSULTATION	DISPOSITION
1. Caustic keratoconjunctivitis	<p>Immediate and copious irrigation with tap water or sterile normal saline until tear-film pH = 7.</p> <p><i>Solids:</i> lift particles out with dry swab before irrigation</p> <p><i>Acids:</i> minimum of 2 L and 20 min</p> <p><i>Alkalis:</i> minimum of 4 L and 40 min</p> <p>None except artificial tears for dry eye.</p>	<p>Ophthalmologist must come to ED if there is any abnormal visual acuity or objective finding on examination after sufficient irrigation, with exception of expected injection of conjunctiva secondary to treatment.</p>	<p>May discharge only if tear film pH = 7 and no findings on examination except conjunctival injection and ophthalmologist can reevaluate next day.</p>
2. Blepharitis Inflammation of eyelid margins often a/w crusts on awakening, FB sensation, and tearing.	None	Outpatient referral only for treatment failure after 2 wk.	Discharge with instructions to apply warm compresses to eyelids for 15 min qid and scrub lid margins and lashes with mild shampoo on washcloth bid.
3. Chalazion Inflammation of meibomian gland causing subcutaneous nodule within the eyelid.	None.	Outpatient referral only for treatment failure after 2 wk.	Discharge with instructions to apply warm compresses to eyelids for 15 min and gently massage nodule qid.
4. Dacryocystitis and dacryadenitis Eye tearing and inflammation of lower eyelid inferior to lacrimal punctum finding redness and tenderness over nasal aspect of lower lid and adjacent periorbital skin.	<p>First r/o periorbital cellulitis (#9) and orbital cellulitis (#7). Inspect for obstruction of punctum by SLE, may express pus by pressing on sac. PO Rx for nasal and skin flora if not admitting.</p>	<p>Ophthalmologist may admit if systemically ill, case is moderate or severe, or no social support for patient. Ask about culturing before Rx if admitting, then Rx same as for periorbital cellulitis (#9).</p>	<p>May discharge mild cases with PO analgesics and antibiotics (e.g., amoxicillin/clavulanate), and instructions to apply warm compresses to eyelids for 15 min and gently massage inner canthal area qid.</p>
5. Hordeolum (a.k.a. sty) Abscess in eyelash follicle or modified sebaceous gland at lid margin: <i>external</i> or <i>internal</i> based on side of lid margin that abscess is pointing.	<p><i>External:</i> Warm compresses often all that is needed, may Rx anti-<i>Staph</i> ointment bid.</p> <p><i>Internal:</i> PO Rx for β-lactamase <i>Staph</i>.</p>	<p>Outpatient referral only for treatment failure after 2 wk.</p>	<p>Discharge with instructions to apply warm compresses to eyelids for 15 min and gently massage abscess qid.</p>
6. Inflammatory pseudotumor* Nonspecific idiopathic retrobulbar inflammation with eyelid swelling, palpebral injection of conjunctiva, chemosis, proptosis, blurred vision, painful or limited ocular mobility, binocular diplopia, edema of optic disk, or venous engorgement of retina.	<p>Measure IOP. Evaluate for infection, diabetes mellitus, and vasculitis with CBC, BMP, UA, and ESR. Obtain axial CT of brain and axial and coronal CT of orbits and sinuses.</p>	<p>IOP > 20 mm Hg may be surgical emergency, Rx to decrease IOP in ED.</p>	<p>May discharge if no systemic problems, no findings of particular concern on CT, and IOP > 20 mm Hg. Start high-dose PO steroids after discussion with ophthalmologist and ensure reevaluation in 2–3 days.</p>
7. Orbital cellulitis* Eyelid swelling, redness and warmth of skin overlying orbit, tenderness of skin overlying bone palpebral injection of conjunctiva, and chemosis. Differentiated from periorbital cellulitis by presence of any finding of fever, ill appearance, blurred vision, proptosis, painful or limited ocular mobility, binocular diplopia, edema of optic disk, or venous engorgement of retina.	<p>Measure IOP. Start IV Rx with second-generation cephalosporin (e.g., cefuroxime, cefoxitin, or cefotetan) or with ampicillin/sulbactam to cover sinus and skin flora. Alternative Rx is ticarcillin/clavulanate, piperacillin/tazobactam, vancomycin, or clindamycin + third-generation cephalosporin (e.g., cefotaxime or ceftriaxone).</p>	<p>IOP > 20 mm Hg may be surgical emergency, Rx to decrease IOP in ED. Obtain blood cultures and start antibiotics. Axial and coronal CT of orbits and sinuses to r/o FB, retrobulbar abscess, orbital gas, subperiosteal abscess, osteomyelitis, and changes in cavernous sinus. Consider LP.</p>	<p>Admit all cases of orbital cellulitis.</p>
8. Orbital tumor* Blurred vision, proptosis or other displacement of globe, painful or limited ocular mobility, or binocular diplopia (but can be asymptomatic).	<p>Measure IOP. Evaluate for extraocular signs of malignancy. Obtain axial CT of brain and axial and coronal CT of orbits and sinuses.</p>	<p>IOP > 20 mm Hg may be surgical emergency, Rx to decrease IOP in ED. Ophthalmologist may want MRI, MRA, or orbital US.</p>	<p>Based on findings and discussion with consultant.</p>

Continued

Table 32-2 Management Algorithm for Red Eyes Extended from Diagnostic Algorithm in Figure 32-10—cont'd

DIAGNOSIS FROM FIGURE 32-10	MANAGEMENT	CONSULTATION	DISPOSITION
9. Pteriorbital cellulitis or erysipelas Eyelid swelling, redness and warmth of skin overlying orbit, tenderness of skin overlying bone, palpebral injection of conjunctiva, and chemosis. Differentiated from orbital cellulitis by <i>absence</i> of any other finding listed in #7.	First r/o orbital cellulitis (#7). PO Rx for sinus and skin flora if not admitting.	Ophthalmologist may admit if systemically ill, case is moderate or severe, or no social support for patient.	May discharge mild cases with PO antibiotics. Ophthalmologist must reevaluate next day to ensure no orbital extension.
10. Retrobulbar abscess* Findings of orbital cellulitis (#7) but a/w increased IOP.	Measure IOP unless possibility of ruptured globe. IOP > 30 mm Hg may require emergent needle aspiration or lateral canthotomy and cantholysis in ED.	IOP > 20 mm Hg may be surgical emergency, Rx to decrease IOP in ED. Obtain axial CT of brain and axial and coronal CT of orbits and sinuses.	Admit all cases of retrobulbar pathology causing increased IOP. Others might be candidates for discharge depending on cause of problem.
11. Retrobulbar emphysema* Findings of pseudotumor (#6) but a/w increased IOP.	<i>Abscess:</i> Antibiotics as in orbital cellulitis (#7). <i>Emphysema:</i> Prophylax with antibiotics to cover sinus flora. <i>Hematoma:</i> Correct any coagulopathy or thrombocytopenia.		
12. Retrobulbar hematoma* Findings of pseudotumor (#6) but occurs due to trauma, coagulopathy, or thrombocytopenia and a/w diffuse subconjunctival hemorrhage anteriorly and extending posteriorly as well as increased IOP.			
13. Keratitis (abrasion or UV injury) Pain, FB sensation, blepharospasm, tearing, photophobia, epithelial disruption on inspection under white light or fluorescein pooling under blue light. SPK appears as stippling of corneal surface [often lower 2/3 of cornea if due to light exposure].	First r/o corneal penetration either grossly or employing Seidel's test. Relieve pain and blepharospasm with topical anesthetic. Inspect all conjunctival recesses and superficial cornea for any foreign material that can be removed by irrigation or manually lifted from surface. Tetanus prophylaxis is standard of care even if cornea not penetrated.	Ophthalmologist must come to ED if there is any concern for globe penetration. Otherwise consult for follow-up examination in 1–2 days. One-time administration of cycloplegic agent may limit photophobia until follow-up examination.	May discharge cases not infected or ulcerated on topical antibiotic prophylaxis using polymyxin B combinations with bacitracin (ointment) or trimethoprim (solution). Gentamicin and sulfacetamide are less desirable single-agent alternatives. PO NSAIDs or narcotics for analgesia. Patching not necessary.
Keratitis (ulceration)* Symptoms and signs as above. Ulceration from complications of contact wear or neglected corneal abrasion has "scooped out" epithelium with surrounding edema appearing as white "cloudiness" in clear tissue.	Relieve pain and blepharospasm with topical anesthetic. <i>Staph.</i> and <i>Strep.</i> species still most common organisms, but <i>Pseudomonas</i> (especially contact lens wearer), so Rx with topical fluoroquinolone is preferred.	Discuss any potential need to débride or culture before starting antibiotic.	Based on findings and discussion with consultant. Typical ciprofloxacin dosing is 1 gt. q 15 min for 1 hr, then 1 gt. q hr for 8 hr, then 1 gt. q 4 hr until seen by consultant next day. PO NSAIDs or narcotics for analgesia. No patch.
Keratitis (herpetic infection)* Symptoms and signs as above. Look for other signs of herpes, varicella, zoster (or CMV infection in immunocompromised patient). Look for "dendritic" defects of cornea with fluorescein under blue light.	Relieve pain and blepharospasm with topical anesthetic. Rx with trifluridine 1% solution, vidarabine ointment, or acyclovir ointment. Varicella-zoster and CMV not normally given antivirals if immunocompetent.	Discuss with ophthalmologist any potential need to débride or culture before starting antiviral.	Based on findings and discussion with consultant. Typical trifluridine dosing is 1 gt. q 2 hr for 7 days, then taper over 2 more wk. Typical vidarabine or acyclovir dosing is five times a day for 7 days, then taper over 2 more wk. PO NSAIDs or narcotics for analgesia. No patch.

<p>14. Keratoconjunctivitis Conjunctivitis with subepithelial infiltrates in cornea causing pain and decreased vision, possibly with halos reported.</p>	<p>Treat for conjunctivitis by likely etiologic category (#25–30).</p>	<p>Discuss findings and use of prednisolone acetate 1% (frequency determined by ophthalmologist).</p> <p>May discharge patient with medications recommended by ophthalmologist and ensure reevaluation in 2–3 days.</p>
<p>15. Episcleritis* Rapid onset of localized pain, injection of episcleral vessels, and localized tenderness.</p>	<p>Relieve irritation with artificial tears and decrease inflammation with ketorolac gtt.</p>	<p>Outpatient referral only for treatment failure after 2 wk.</p> <p>May discharge patient with PO NSAIDs alone or in combination with topical ketorolac gtt.</p>
<p>16. Scleritis* Progressively increasing eye pain with radiation to ipsilateral face and decreasing vision, photophobia, tearing, and possible pain with eye motion.</p>	<p>Decrease inflammation with PO NSAIDs.</p>	<p>Discuss findings and use of topical or PO steroids.</p> <p>May discharge patient with medications recommended by ophthalmologist and ensure reevaluation in 2–3 days.</p>
<p>17. Anterior uveitis and hypopyon* Eye pain, photophobia, tearing, limbal injection of conjunctiva, and cells or flare in anterior chamber. Hypopyon is layering of white cells (pus) in anterior chamber.</p>	<p>First r/o glaucoma with IOP measurement. Rx in ED if IOP > 20 mm Hg. Otherwise OK to dilate pupil with 2 gtt. of cyclopentolate 1%.</p>	<p>Discuss findings and use of prednisolone acetate 1% (frequency determined by ophthalmologist but range is q 1–6 hr).</p> <p>May discharge patient with medications recommended by ophthalmologist and ensure reevaluation in 2–3 days. Patients with hypopyon are generally admitted.</p>
<p>18. Acute angle-closure glaucoma Sudden-onset eye pain and blurred vision that may be a/w frontal headache, nausea, and vomiting. Anterior eye may manifest shallow or closed angle between iris and cornea, pupil fixed in mid-dilation, or limbal injection of conjunctiva.</p>	<p>Decrease production of aqueous humor. Timolol 0.5% 1 gt., then repeat in 30 min. Apraclonidine 1% 1 gt. once. Dorzolamide 2% 2 gtt. or if <i>sickle cell disease or trait</i> then methazolamide 50 mg PO. Decrease inflammation. Prednisolone 1% 1 gt. every 15 min four times.</p> <p>Constrict pupil. Pilocarpine 4% 1 gt., then repeat in 15 min</p> <p>Consider establishing osmotic gradient Mannitol 2 g/kg IV.</p>	<p>Based on findings and discussion with consultant, which primarily depends on speed of onset and response to treatment.</p> <p>Discuss any IOP > 20 mm Hg with ophthalmologist.</p>
<p>Rx in ED if IOP > 30 mm Hg.</p>	<p>First r/o globe rupture. May require ultrasound if cannot visualize posterior structures. Measure IOP unless possibility of ruptured globe. IOP > 30 mm Hg may require acute treatment as in glaucoma (#18). If IOP > 20 mm Hg and no iridodialysis, may use cycloplegic to prevent iris motion.</p>	<p>Most patients can be discharged with careful instructions to return for any increased pain or change in vision. Patients should decrease physical activity and sleep with an eye shield in place. Eyes should be left open while awake, so any change in vision can be immediately recognized. PO NSAIDs or narcotics for analgesia.</p>
<p>19. Hyphema* Pain, decreased visual acuity, gross or microscopic blood in anterior chamber, may be a/w dilated and fixed pupil following blunt trauma. Graded by amount of blood. Percentage of vertical diameter of anterior chamber when blood layers with patient in upright position. Microhyphema shows no layering and only suspended red blood cells.</p>	<p>Discuss findings and use of ε-aminocaproic acid and steroids, other medical therapy, best disposition, and follow-up examination by ophthalmologist within 2 days. Some patients may be admitted for observation, bed-rest, head elevation, and frequent medication administration.</p>	<p>Most patients can be discharged with careful instructions to return for any increased pain or change in vision. Patients should decrease physical activity and sleep with an eye shield in place. Eyes should be left open while awake, so any change in vision can be immediately recognized. PO NSAIDs or narcotics for analgesia.</p>

Continued

Table 32-2 Management Algorithm for Red Eyes Extended from Diagnostic Algorithm in Figure 32-10—cont'd

DIAGNOSIS FROM FIGURE 32-10	MANAGEMENT	CONSULTATION	DISPOSITION
20. Endophthalmitis* Progressively increasing eye pain and decreasing vision, diminished red reflex, cells and flare (and possibly hypopyon) in anterior chamber, chemosis, and eyelid edema.	Empirical parenteral antibiotic administration with cefazolin + gentamicin or vancomycin + cefotaxime, ceftazidime, or ceftriaxone to cover <i>Bacillus</i> , <i>enterococcus</i> , and <i>Staphylococcus</i> spp. Decrease inflammation with naphazoline or ketorolac gtt.	Ophthalmologist must admit for parenteral and possibly intraocular antibiotics. Outpatient referral only for treatment failure after 2 wk.	Admit all cases of endophthalmitis. Discharge to follow-up with ophthalmologist for possible steroid therapy or surgical removal. Same as #21
21. Inflamed pinnaculum Inflammation of soft yellow patches in temporal and nasal edges of limbal margin.	Same as #21	Same as #21	Same as #21
22. Inflamed artery Inflammation of firmer white nodules extending from limbal conjunctiva onto cornea.	Same as #21	Same as #21	Same as #21
23. Scleral penetration* Localized redness at site of entry, teardrop pupil, blood in anterior chamber or loss of red reflex.	Protect eye from further pressure, provide pain relief, and prevent vomiting. Tetanus prophylaxis. Exclude coagulopathy or thrombocytopenia, if indicated by history.	Ophthalmologist must come to ED if there is any concern for globe penetration. None required if no complications.	Admit for IV antibiotics and possible procedural intervention. Reassure patient that red should resolve over 2–3 wk.
24. Subconjunctival hemorrhage Red blood beneath clear conjunctival membrane.	Topical polymyxin B trimethoprim in infants and children, because more <i>Staph.</i> spp. Topical sulfacetamide or gentamicin clinically effective in 90% of uncomplicated adult cases. Use topical fluoroquinolone if <i>Pseudomonas</i> possible.	Culture drainage and ophthalmology consult in all neonates and those at risk for vision loss or systemic sepsis. <i>Neisseria gonorrhoeae</i> can be rapidly sight-threatening.	Discharge uncomplicated cases with 10 days of topical antibiotics in both eyes, regardless of laterality of apparent infection. Use ointments in infants and gtt. in others.
25. Bacterial conjunctivitis* Hyperpurulent discharge not typical of common “pink eye” and more commonly unilateral in adults. Inflammation of eyelid margins a/w lid edema, chemosis, and possibly subconjunctival hemorrhage, but usually no follicular “cobblestoning.”	Decrease irritation with naphazoline gtt.	Outpatient referral only for treatment failure after 2 wk.	Identify antigen if possible. Consider treating other allergic symptoms with PO antihistamines.
26. Allergic conjunctivitis Often bilateral palpebral injection of conjunctiva and follicular cobblestoning of inner surface of lids that may be seasonal and a/w other allergic symptoms such as rhinitis.	Irrigation with tap water or sterile normal saline. Decrease irritation with naphazoline gtt.	Outpatient referral only for severe cases or treatment failure after 2 wk.	Identify offending agent and avoid subsequent exposure. Discharge uncomplicated cases on continued naphazoline. Same as #27
27. Contact dermatitis/conjunctivitis Localized lid and conjunctival redness and edema.	Same as #27	Same as #27	Same as #27
28. Toxic conjunctivitis Diffuse conjunctival injection, chemosis, and lid edema.	Rx PO azithromycin for <i>Chlamydia</i> . Consider parenteral ceftriaxone for concurrent <i>Neisseria gonorrhoeae</i> .	Culture drainage and consult ophthalmology in all neonates and those at risk for vision loss or systemic sepsis.	Discharge uncomplicated cases on 5 days of PO azithromycin.
29. <i>Chlamydia</i> conjunctivitis Often bilateral palpebral injection of conjunctiva in neonate or other individual at risk for sexually transmitted disease.	Decrease irritation with artificial tears, naphazoline, or ketorolac gtt.	Culture drainage and consult ophthalmology in all neonates and those at risk for vision loss or systemic sepsis.	Ask about pregnant mothers, infants, and immunocompromised individuals in close contact. Discharge uncomplicated cases with instructions on respiratory and direct-contact contagion for 2 wk.
30. Viral conjunctivitis Often bilateral palpebral injection of conjunctiva and follicular cobblestoning of inner surface of lids. Inflammation of eyelid margins often a/w crusts on awakening, FB sensation, and tearing.			

*Potentially serious diagnoses if not identified on initial emergency department evaluation. Antibiotic choices should be based on current practice.

a.k.a., also known as; a/w, associated with; bid, twice daily; BMP, basic metabolic profile (includes electrolytes, glucose, and renal function tests); CBC, complete blood count; CMV, cytomegalovirus; CT, computed tomography; ED, emergency department; ESR, erythrocyte sedimentation rate; FB, foreign body; gt., drop; gtt., drops; IOP, intraocular pressure; LP, lumbar puncture; MRA, magnetic resonance angiography; MRI, magnetic resonance imaging; NSAIDs, nonsteroidal anti-inflammatory drugs; PO, oral; q, every; qid, 4 times a day; r/o, rule out; Rx, prescribe; SLE, slit-lamp examination; SPK, superficial punctuate keratitis; spp, species; *Staph.*, *Staphylococcus*; *Strep.*, *Streptococcus*; UA; urinalysis; US, ultrasonography; UV, ultraviolet.

Trauma

Blunt trauma is a common cause of a red and painful eye. Large hyphemas and those with clots are likely to require hospitalization for bedrest with 30° of head elevation. Systemic analgesia and, if required, antiemetics are indicated. Medications affecting platelet function should be avoided. Treatment may be indicated when the IOP exceeds 30 mm Hg, as it is in acute angle-closure glaucoma. If the iris is not injured, a long-acting cycloplegic agent (e.g., topical homatropine) may be recommended to prevent repetitive motion of the iris. Some reliable adult patients may be discharged with daily follow-up by a specialist. Strong analgesia and patching are not indicated, so that the patient may immediately identify increases in pain or decreases in visual acuity.

Corneal abrasions are common problems in the emergency department. When the emergency physician is convinced that the cornea has not received a full-thickness laceration or penetration by a foreign body, management is relatively simple. Foreign bodies (on or in the epithelium only) should be removed when possible. These may frequently adhere to a saline-moistened cotton-tipped applicator. Ones that do not may sometimes be lifted off with a blunt-tipped tool (“spud”) under the binocular magnification of a slit lamp. The common use of hypodermic needle removal may damage surrounding cornea and is not recommended. Whether or not the object can be successfully removed, management is the same as for corneal abrasions. Rust staining of the corneal epithelium does not require removal in the emergency department, but patients are referred to a specialist for examination within 3 days. Prophylactic topical antibiotics are indicated for all epithelial defects of the cornea. Patching is not necessary and may be harmful. Systemic analgesia appropriate to the patient’s level of pain should be provided. Larger lesions may require a prophylactic mydriatic or cycloplegic agent anticipating a secondary iritis. Topical anesthetics should not be given to the patient for home use.⁴

DISPOSITION

Most emergency department patients with eye complaints are candidates for discharge and, if indicated, follow-up in the

emergency department or with an ophthalmologist in 1 to 2 days. Others may require referral only if there is lack of resolution or treatment fails. A few patients require admission for procedural intervention, parenteral antibiotic regimens, management of intractable pain, or further diagnostic evaluation. General consultation and disposition considerations for the most important entities are outlined in Table 32-2.

KEY CONCEPTS

- Prompt and prolonged irrigation is advised for patients who experience caustic injury to the eye.
- Headache and nausea may be prominent symptoms in patients with acute angle-closure glaucoma.
- Keratitis, inflammation of the cornea, is most commonly caused by a viral infection, but may also be caused by recent ultraviolet light exposure, chemical injury, or hypoxic injury from contact lens use.
- A localized corneal defect with edematous, inflammatory changes may signal corneal ulceration.
- A corneal dendritic pattern may signal a herpetic infection, which can progress to corneal opacification and visual loss.
- Pain, consensual photophobia, perilimbal conjunctival infection, and a miotic pupil that is caused by ciliary spasm could signal iritis, which is inflammation of the iris and ciliary body, or uveitis, inflammation of the iris, ciliary body, and also choroids. The cause may be trauma or underlying autoimmune disease. The presence of cells and flare in the anterior chamber can help signal these conditions.

The references for this chapter can be found online by accessing the accompanying Expert Consult website.